CHAPTER
40 The knee

Learning objectives

To understand:

- The anatomy and biomechanics of the knee and their clinical implications
- The clinical presentation, aetiology and management of common knee pathologies
- The principles of joint replacement, including important complications
- The advances in surgical practice in this field

APPLIED ANATOMY

The knee joint is a synovial hinge joint. It consists of two condyloid tibiofemoral joints and a sellar (or saddle shaped) patellofemoral joint. The shape makes the joint inherently unstable, but stability is achieved by a combination of static (ligaments) and dynamic (muscles) stabilisers acting across the joint.

Interposed between the tibia and femoral condyles are the medial and lateral menisci. These fibrocartilaginous structures aid shock absorption, increase the area over which load is dissipated and have a role in anteroposterior stability (*Figure 40.1*). Loss of the protective function of the meniscus through injury, degeneration or meniscectomy can accelerate degenerative change and progression to arthritis. Medial meniscal tears are three times more common than those in the more mobile lateral meniscus. Tears or meniscectomy that disturb the circumferential fibres and defunction the protective hoop stresses (such as radial tears, disruption of the root attachments or removal or large portions of the meniscus) can cause rapid deterioration of the joint.

The medial and lateral collateral ligaments are the primary restraints to valgus and varus stress, respectively. The medial collateral ligament (MCL) is a broad, flat ligament composed of a superficial and a deep layer. The deep layer is attached to the medial meniscus and to the tibia, close to the joint. The superficial MCL attaches more distally on the tibia. The MCL is commonly injured, but frequently heals with conservative management. The lateral collateral ligament (LCL) is a simple cord-like structure but works in combination with other structures (including the popliteus, biceps, popliteofibular ligament, iliotibial band, joint capsule) to form the lateral/posterolateral ligament complex. Injuries to the LCL are less likely to heal with conservative management and are more likely to require reconstruction.

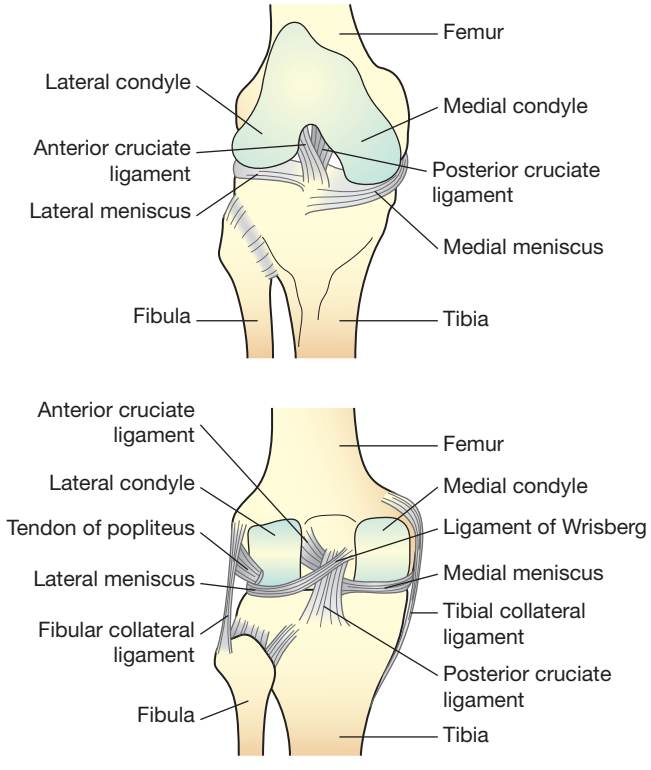

Figure 40.1 Anatomy of the knee joint.

The anterior and posterior cruciate ligaments are each made up of two bundles. The anterior cruciate ligament (ACL) has an anteromedial bundle that is tight in flexion and a posterolateral bundle that is tight in extension. The posterior cruciate ligament (PCL) has an anterolateral bundle (tight in flexion) and a posteromedial portion (tight in extension). The ACL and PCL prevent anterior and posterior translation of

Heinrich A Wrisberg, 1739–1808, German anatomist and gynaecologist.

the tibia on the femur, respectively. Single ligament or meniscal injuries are more likely to occur during sport. Multiple ligament injuries completely disrupt two or more of the four main ligaments and are associated with high-energy trauma such as car crashes. This can result in complete dislocation of the joint and damage to arteries and nerves.

Hyaline articular cartilage is a highly specialised connective tissue that lines the joint surface and has a low coefficient of friction. Hyaline cartilage is devoid of blood vessels, lymphatics and nerves and has a limited capacity for repair. The configuration of cartilage changes with ageing and with disease predisposing to injury.

The knee has bursae surrounding it that can become inflamed and infected.

Summary box 40.1

Anatomy of the knee joint

- Complex synovial hinge joint
- The shape of the joint surfaces makes it inherently unstable
- The static stabilisers are the joint capsule, menisci, cruciate and collateral ligaments
- The dynamic stabilisers are the quadriceps and hamstring muscles

BIOMECHANICS

Axes of the lower limb

The anatomical axes of the femur and tibia are defined by their medullary canal. The mechanical axis of the lower limb runs from the centre of the femoral head, through the intercondylar notch of the knee to the centre of the ankle joint. The angle between the anatomical and mechanical axes of the femur is usually between 5° and 7° (often called the valgus cut angle in arthroplasty) (*Figure 40.2*). A total knee replacement (TKR) is traditionally performed with the goal of lining up the components using cuts perpendicular to the mechanical axis. Knees with malalignment are more prone to injury or degeneration in the loaded compartment. Realignment surgery (tibial or femoral osteotomy) can offload the damaged compartment to reduce symptoms and slow progression to arthritis.

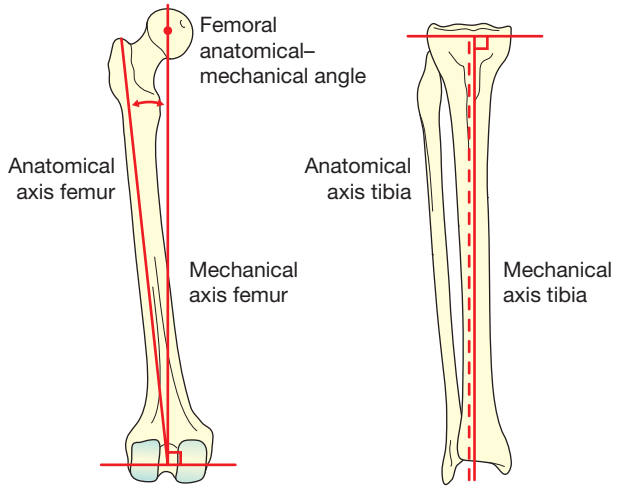

Figure 40.2 Axes of the lower limb. Anatomical and mechanical axes are coincident in the tibia but not the femur. (Adapted from Miller M. *Review of orthopaedics*, 4th edn. Philadelphia: Elsevier, 2004. By kind permission of the publishers.)

Kinematics and kinetics

Knee motion is predominantly in the sagittal plane. A limited degree of rotation also occurs and increases as knee flexion increases. The normal range of motion is between 5° of hyperextension and 135° of flexion. Magnetic resonance imaging (MRI) of cadaveric knees has revealed that, during knee flexion, a combination of rolling and sliding of the femur on the tibia occurs in addition to internal rotation of the tibia. This is because the larger medial femoral condyle rolls back less than the smaller lateral femoral condyle. This motion is facilitated by a more mobile lateral meniscus and lateral ligaments that are more lax in flexion.

The biomechanical role of the patella is to function as a pulley for the quadriceps. It increases the power of the quadriceps by increasing the lever arm. It has the thickest articular cartilage in the body and is designed to withstand loads as high as 20 times body weight when jumping. Abnormal alignment, surface contour, soft-tissue constraints or muscle balance can result in patellar dislocation.

Summary box 40.2

Biomechanics of the knee joint

- The femur has different anatomical and mechanical axes because of the offset of the proximal femur at the hip. These axes are the same in a normal tibia
- Knee motion is mainly in the sagittal plane with some rotation
- The patella acts as a pulley, increasing the lever arm of the quadriceps
- Loads of up to 20 times body weight are transmitted across the patella when jumping

CONDITIONS AFFECTING THE KNEE JOINT

The commonest conditions affecting the knee include injury to the soft-tissue structures and osteoarthritis (OA).

Soft-tissue knee problems

These can present as acute injures or as delayed, more chronic cases with additional degenerative problems. Specific structures commonly involved are the menisci, ligaments and tendons. These can also be associated with chondral or osteochondral injury.

Meniscal tears

The pattern of meniscal injury or degeneration is variable and can affect either the medial and/or the lateral meniscus.

There are several recognised patterns of meniscal tear: circumferential, radial, horizontal, flap and degenerate. MRI scan is the investigation of choice for identifying meniscal tears. Meniscal tears seldom heal. Meniscal tears associated with a specific injury or with mechanical symptoms, e.g. catching, locking and giving way, generally respond well to arthroscopic repair or debridement. Factors making a tear amenable to repair include younger age of patient, early presentation, simple tear configuration, knee stability and a tear in the vascular outer third of the meniscus. Degenerate tears in ageing joints, without an episode of injury and without mechanical symptoms, are primarily treated conservatively with arthroscopy considered after failure of conservative treatment.

Anterior cruciate ligament injury

The ACL rupture is the most common serious ligament injury in the knee. Injury is usually caused by a twisting or landing injury in a pivoting sport. It may be associated with an audible 'pop', immediate swelling and the need to be 'carried off' the field. The injury risk is higher among females; this is thought to be due to smaller ligaments, smaller femoral notches and different landing biomechanics. ACL deficiency can cause instability resulting in further damage to other structures, complex meniscal tears and chondral injury. Examination findings confirming an ACL injury include a positive Lachman test and a positive pivot shift test. MRI scan confirms the ACL rupture and identifies possible injury to secondary structures such as meniscus or cartilage.

Isolated ACL injuries are generally initially managed non-operatively with a knee brace, painkillers, swelling reduction and physiotherapy. Surgical reconstruction is considered in multiligament injuries, in cases of persisting instability after non-operative management, or in young patients or high-demand athletes who tend to fail conservative treatment (see *Chapter 36*). Surgical reconstruction of the ACL is best undertaken when the knee has recovered from the acute injury and has a good range of knee motion and muscle function.

Extensor mechanism rupture

This includes ruptures of either the quadriceps or patellar tendons. These are usually high-energy injuries but can occur more easily in those on steroids, following steroid injections or following previous open knee surgery that may have compromised the blood supply to these structures. They usually present with significant pain and swelling and the inability to actively extend the knee. Prompt surgical repair or reconstruction is required to avoid a significant long-term loss of knee function.

Articular cartilage injury

These can occur in isolation or in association with ACL injuries or patellar dislocations. Partial-thickness defects do not show any potential to heal. Full-thickness defects in younger patients may mount a healing response with fibrocartilage. In higher energy injury, bone may be included in the surface fragment (osteochondral injury). If picked up acutely the chondral and osteochondral lesions may be surgically fixed back in place. Delayed options for full-thickness defects include: removal of the loose body, microfracture, microfracture covered by a collagen membrane, osteochondral transplant (mosaicplasty) or chondrocyte transplant. Chondrocyte transplant usually involves autologous chondrocyte implantation (ACI) or matrix-assisted ACI (MACI). The age of the patient and the site and size of the defect determine the most appropriate treatment.

Osteoarthritis

OA commonly affects the knee joint. The prevalence of symptomatic knee OA in adults aged 60 years or older is approximately 10% in men and 13% in women. OA can be either primary (idiopathic) or secondary. Patients with primary OA tend to have other joints involved and may have a family history of arthritis. Secondary OA may occur following a previous intra-articular fracture, meniscectomy, ligament injury, osteonecrosis or in a neuropathic joint.

Clinical features

Patients usually describe pain, stiffness and swelling. Pain is usually worse with loading and with activity. Patellofemoral OA pain is worse on stairs and rising from a seated position. The natural history of OA is of a gradual steady deterioration from episodes of short-lived flare-ups progressing to constant pain that often affects sleep. Mobility deteriorates, walking distance reduces and walking aids are frequently required. In severe cases, patients may become dependent on a wheelchair or become housebound.

Examination reveals an antalgic gait in which the patient limps, spending a short time on the painful limb, and moves their centre of gravity to minimise the weight they are taking through this limb. In knee OA the deformity is usually varus, with bone loss on the medial side. Valgus deformity is more common in women, in rheumatoid arthritis and after lateral meniscectomy. The joint appears bulky owing to effusion, synovial thickening and growth of osteophytes. An effusion is frequently present and movement, particularly extension, is restricted. Crepitus can be both palpable and audible.

Investigation

Plain radiographs are the investigation of choice with typical features of joint space narrowing, subchondral sclerosis, osteophytes and subchondral cysts (*Figure 40.3*). These are best performed weight-bearing to show the extent of joint narrowing. MRI scan is not routinely required prior to knee replacement.

Treatment

Non-operative methods are the first line of treatment. Patients should be encouraged to lose weight, undertake regular exercise to prevent joint stiffness and use anti-inflammatory medication. Walking aids, such as a stick, orthotics and off-loader braces, may be beneficial. Intra-articular steroid injections can be used to settle an arthritic flare-up but are no longer recommended as a long-term solution because of concerns about infection and causing further joint cartilage damage.

John W Lachman, 1919–2007, Professor and Chairman of the Orthopedic Department at Temple University in Philadelphia, PA, USA.

Figure 40.3 Anteroposterior (a) and lateral (b) radiographs of osteoarthritis of the knee.

Surgical options include osteotomy, partial knee replacement, TKR or arthrodesis.

Summary box 40.3

Knee OA

- More common in females
- Can be primary (idiopathic) or secondary (e.g. post traumatic)
- The main symptom is pain made worse by use
- Examination reveals swelling and a reduced range of motion with or without deformity
- The key radiographic features are joint space narrowing, subchondral sclerosis and cysts, and osteophytes
- Treatment is non-operative initially. Knee replacement is reserved for end-stage disease

SURGICAL PROCEDURES

Knee operations can be done either arthroscopically or open. Arthroscopic treatment is possible for most soft-tissue problems, while open surgery is required for osteotomy, replacements and arthrodesis. Procedures amenable to arthroscopic treatment are summarised in *Table 40.1*.

Meniscal surgery

This is performed arthroscopically, commonly using two portals, usually as a day case under general anaesthetic. The meniscus is inspected to define the configuration of the tear and whether it is in a part of the meniscus with sufficient blood supply to allow healing. If the tear is not amenable to repair, a combination of punches and arthroscopic shavers are used to remove any unstable or unhealthy meniscus, back to a healthy stable rim. Attempts should be made to repair meniscal tears in the young, and if the tear is repairable; commonly these will be circumferential or 'bucket-handle' tears. Repair includes freshening the repair site and then fixation with a combination of inside-out, outside-in or all-inside sutures or meniscal repair devices. Postoperative protection of the repair usually includes restriction of weight-bearing and use of a brace for between 6 weeks and 3 months.

TABLE 40.1 Indications for knee arthroscopy.

- Torn meniscus resection or repair
- Anterior/posterior cruciate ligament reconstruction
- Loose body removal
- Cartilage regeneration techniques, including microfracture
- Septic arthritis washout
- Inflammatory arthritis and pigmented villonodular synovitis (PVNS) – synovectomy
- Diagnosis of unexplained knee pain
- Tibial plateau fractures – allows intraoperative assessment and reduction of the articular surface

Cruciate reconstruction

An isolated ACL injury is most commonly treated with an arthroscopic intra-articular reconstruction. The graft can be a bone–patellar tendon–bone or four-strand hamstring autograft. Screws or fixation devices hold the graft in bone tunnels in the femur and tibia until it has healed. Return to full sport can take up to a year. Postoperative rehabilitation programmes are crucial to a favourable outcome. Complications following ACL surgery are usually a result of incorrect tunnel placement (placing the femoral tunnel too far anteriorly limits knee flexion) and early surgery. The graft re-rupture rate is approximately 1% per year.

Osteotomy

Varus or valgus alignment or deformity of the knee can abnormally load the medial or lateral compartment, resulting in premature degenerative change in that compartment. Osteotomy aims to divide the bone, correct the deformity and alter the load-bearing mechanics of the joint. The most

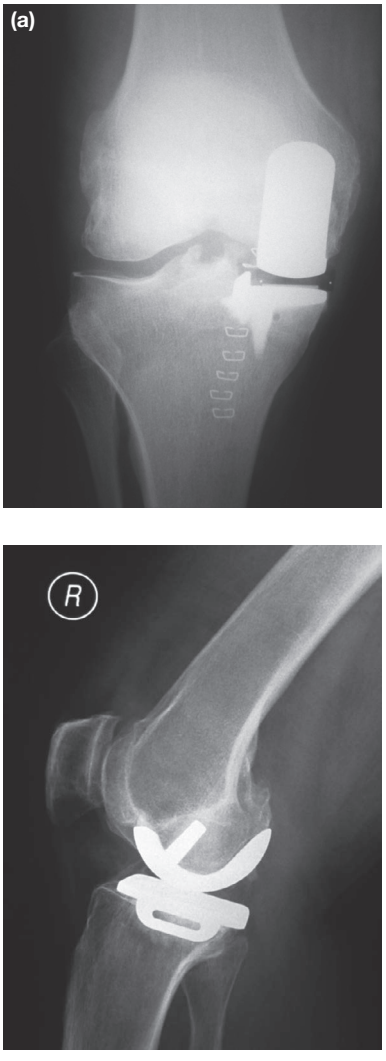

Figure 40.4 Anteroposterior (a) and lateral (b) radiographs of a unicompartmental knee replacement.

commonly performed operation is a high tibial osteotomy (HTO) for a varus knee. Realignment is achieved with either an opening-wedge medial HTO or a closing-wedge lateral HTO. The amount of angular correction is calculated preoperatively and then created in theatre with jigs under radiographic control. Fixation with modern plates and locking screws allows early weight-bearing and mobilisation. The ideal patient for osteotomy is a young, active and well-motivated individual with disease limited to one compartment.

Knee joint replacement

There are three compartments within the knee: medial and lateral tibiofemoral, and patellofemoral. In 20–50% of cases, OA affects only one compartment and these patients may be suitable for a partial or unicompartmental knee replacement (UKR) (*Figure 40.4*), while in tricompartmental disease a TKR is indicated (*Figure 40.5*).

Patients are suitable for UKR if disease is limited to one compartment, if ligaments are intact and if fixed deformity is less than 15°. UKR has complication rates of one-third to one-half

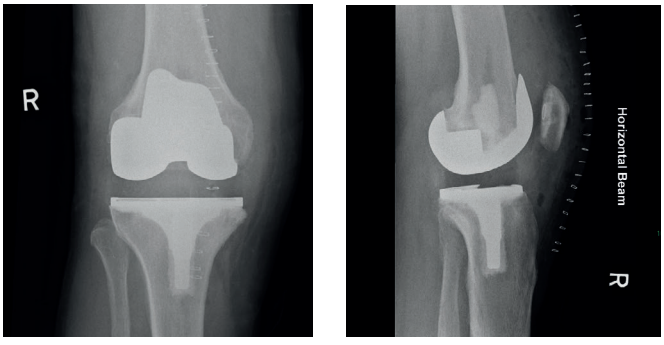

Figure 40.5 Anteroposterior (a) and lateral (b) radiographs of a total knee replacement.

those of TKR with a lower infection rate, lower medical risks and lower risk of death. UKR is associated with a more rapid recovery, shorter hospital stay, preservation of knee kinematics and generally superior function to that of TKR. Revision rates for UKR are significantly influenced by the surgeon's experience and the implant. In optimal conditions the revision rates are similar to TKR, but on national registries UKRs have higher 10-year revision rates (6–12 %) than TKRs (2–6%).

Isolated patellofemoral replacement is also performed but the numbers are low in view of the scarcity of isolated patellofemoral disease. Revision rates are higher than other partial knee replacements, largely because of progression of arthritis in the remaining compartments.

A TKR can be regarded as a resurfacing procedure in which the femoral articular surface is replaced with metal and the tibial articular surface is replaced by a tough polyethylene insert, usually inserted into a metal tibial baseplate. TKR is one of the most successful surgical interventions, with most patients getting significant pain reduction and improvement in mobility. Revision rates are less than 5% at 15 years. Patient satisfaction with TKR is generally lower than that achieved with hip replacement.

TKR implants are generally cemented into the bone using polymethylmethacrylate (PMMA) cement. The design of the articulation can provide varying amounts of stability or constraint. Unconstrained TKRs are the most common and can either retain or sacrifice the PCL; these implants are called cruciate-retaining (CR) or PCL-sacrificing (PS), respectively. The more constrained the implant the greater the force transmitted to the implant–cement–bone interfaces, therefore increasing the risk of loosening. More constrained implants are generally only used in revision cases. If the joint is very unstable or deformed then a hinged knee replacement is used as it does not rely on the ligaments for stability. Modern knee replacements try to reduce wear by using enhanced bearing surfaces such as cross-linked polyethylene, vitamin E-enriched polyethylene or ceramicised surface coatings.

The TKR surgical technique aims to correct the deformity and leave the leg aligned with the mechanical axis and with the joint parallel to the ground. More modern philosophies of TKR try to match the patient's more individual alignment in the hope that this feels more natural to the patient, but it may require additional technology to allow this to be done accurately, e.g. computer navigation or robotics. It is important

that the ligaments and soft-tissue envelope are well aligned and balanced to allow good stability, range of motion and patellar tracking. Early weight-bearing and mobilising are now possible, with some patients treated as day cases but most staying in hospital for 2–4 days.

Complications following TKR can be broadly classified into intraoperative and postoperative (*Table 40.2*).

TABLE 40.2 Complications of total knee replacement.

Intraoperative
- Implant malposition and malalignment; with subsequent contribution to instability, stiffness or pain
- Nerve or vessel injury, including tourniquet damage
- Fracture
- Patellar tendon avulsion
- Fat embolism

Postoperative
- Infection
- Deep vein thrombosis/pulmonary embolism
- Pain/stiffness
- Instability
- Osteolysis
- Component loosening
- Dislocation

Summary box 40.4

Aims of TKR
- Correct deformity caused by arthritis
- Align the knee to the mechanical axis or slightly under-corrected
- Joint line perpendicular to the mechanical axis
- Balanced collateral ligaments
- Ensure patellofemoral joint tracks normally

Knee arthrodesis

Knee arthrodesis is rare and is largely a historic procedure that is seldom acceptable to modern patients. It is therefore used as a salvage option after failure of multiply-revised and infected joint replacements, particularly if there is disruption of the extensor mechanism. It is occasionally considered as a primary intervention in rare cases where neurological abnormality would prevent the patient from having the muscle control necessary to control a knee replacement, e.g. stroke, spina bifida, polio, Charcot arthropathy. The ideal position of fusion is 7° of valgus and 15° of flexion. Arthrodesis can be performed using intramedullary nails, plates or extramedullary fixators.

Revision knee replacement

TKRs have excellent long-term survival, with 82% lasting over 20 years and over 95% lasting 10–15 years. In the first few years, revision surgery is most likely to be due to infection, and non-infective causes, such as instability and malalignment. Beyond 10 years, revision is usually a result of aseptic loosening of components, which is often a result of wear of the plastic insert and polyethylene-induced osteolysis. With any failed joint replacement, infection should be excluded as this can compromise the result of surgery and may require a different surgical strategy, e.g. a two-stage rather than a single-stage procedure. Revision arthroplasty is technically more challenging, requires more complex and expensive implants and has a higher complication rate. When done for the correct indication, results are very good. As with a primary TKR, the goal remains to provide a well-aligned, stable and pain-free knee (*Figure 40.6*).

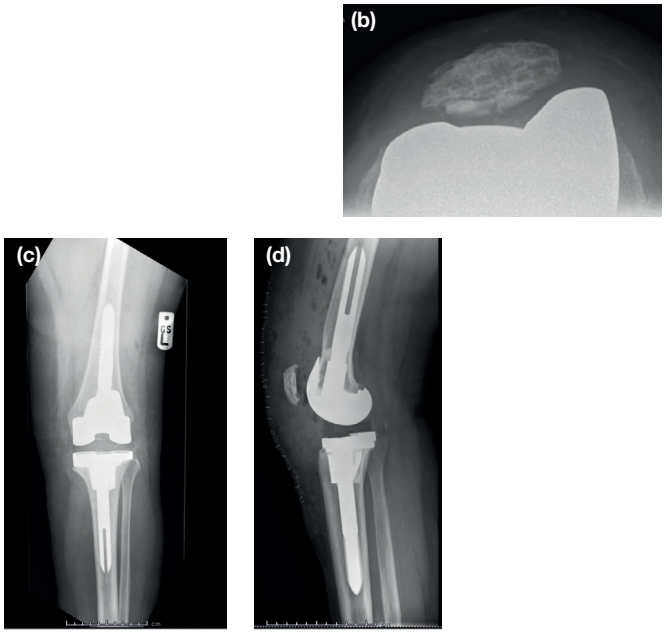

Figure 40.6 Radiographs of a malaligned knee **(a, b)** and a well-aligned revised knee **(c, d)**.

FURTHER READING

Bulstrode C, Wilson MacDonald J, Eastwood D *et al.* *Oxford textbook of trauma and orthopaedics*, 2nd edn. Oxford: Oxford University Press, 2017.

Howells NR, Brunton LR, Robinson J *et al.* Acute knee dislocation: an evidence based approach to the management of the multiligament injured knee. *Injury* 2011; **42**(11): 1198–204.

Miller MD, Thompson SR. *Miller's review of orthopaedics*, 8th edn. Philadelphia, PA: Elsevier, 2019.

National Joint Registry for England, Wales, Northern Ireland and the Isle of Man. *16th annual report 2019*. Hemel Hempstead: National Joint Registry, 2019.

Scott WN. *Insall & Scott surgery of the knee*, 6th edn. Philadelphia, PA: Elsevier, 2017.

Warwick D, Blom A, Whitehouse M. *Apley and Solomon's concise system of orthopaedics and trauma*, 5th edn. Abingdon: CRC Press, 2022.

Jean Martin Charcot, 1825–1893, physician, La Salpêtrière, Paris, France.